

Biliary atresia

Nedim Hadžić

Department of Child Health & Institute
for Liver Studies, King's College Hospital,
London SE5 9RS, UK

Corresponding authors:
Nedim Hadžić
Department of Child Health & Institute
for Liver Studies, King's College Hospital,
London SE5 9RS, UK
nedim.hadzic@kcl.ac.uk

Biliary atresia (BA) remains a puzzling medico-surgical condition more than 100 years after its original description. It is the most important disease in paediatric hepatology and the most frequent indication for liver transplantation in children and young adults. BA occurs sporadically in around 1/17,000 live births in Europe and North America and there is no risk of recurrence within the same family. In patho-anatomical terms, BA is characterised by a progressive ascending obstruction of the biliary tree which evolves into biliary cirrhosis and end stage chronic liver disease within infancy. Corrective surgery – portoenterostomy or the “Kasai operation” can be effective in up to 50-60% of timely operated children, whilst the others should be considered for early liver transplantation. Medical treatment is important to provide optimal nutrition during chronic cholestasis and ensure the normal physical and neurological development of the affected infants. Early and precise diagnosis is of critical importance since delaying surgery may reduce the chances of a successful outcome, while unnecessary surgery for unrecognised other infantile cholestatic conditions is deleterious. Diagnostic algorithms vary depending on the local expertise, but most centres use expert ultrasonography and percutaneous liver biopsy, as clinical examination and biochemical findings are non-specific. Most children with prolonged neonatal conjugated hyperbilirubinaemia will have pale stools, dark urine, a degree of soft hepatosplenomegaly and mildly elevated transaminases. Acholic stools point strongly in the direction of a surgical problem. In ambiguous cases, direct cholangiography, preferably endoscopic retrograde cholangiopancreatography (ERCP), performed at specialized centres, will be diagnostic and spare unnecessary laparotomy, if not indicated. The aetiology of BA remains uncertain. Its inflammatory nature is undoubted and many centres use steroids routinely post-Kasai portoenterostomy in the hope of reducing the inflammatory component and minimising ensuing fibrosis and progression to cirrhosis. The scientific evidence for the benefit of steroids is lacking and there is a lively ongoing research debate about further means of improving the postoperative outcome including the use of steroids at different doses and regimens, and proinflammatory cytokine-blocking agents in the future.

Key words: Neonatal cholestasis, Biliary atresia, Kasai portoenterostomy, Liver transplantation.

Received: 27 September 2009
Accepted: 7 December 2009

Biliary atresia (BA) is a progressive life-threatening obliterative cholangiopathy presenting within the first few weeks of life (1). It occurs sporadically and has no gender preponderance. Its aetiology is unknown and incidence estimates vary from 1/8,000 live births in the Far-East Asia and Oceania to 1/17,000 live births in Europe and North America (2, 3). Untreated BA evolves to end-stage biliary cirrhosis with its complications, leading to death, typically within the first two years of life. Therefore, BA is by far the most frequent indication for liver transplantation (LT) in paediatric medicine (4).

BA is the commonest chronic cholestatic condition in children and typically presents with prolonged neonatal conjugated jaundice, dark urine and acholic stools. These clinical signs are non-specific and could also be noted in some other liver conditions at this age, including non-specific giant-cell hepatitis, PiZ alpha-1-antitrypsin deficiency, Alagille syndrome, cystic fibrosis, bile salt export pump deficiency or septo-optic dysplasia. The key clinical signs are acholic stools, which could initially contain variable amounts of pigment, particularly in the non-syndromic forms of BA, with presumed perinatal or postnatal onset (see later). The variation in this clinical sign, secondary to progressive yet incomplete obstruction of the biliary tree, often with good clinical condition, lack of feeding difficulties and appropriate weight gain, may lead to false reassurance and late diagnosis. Surgical correction of BA has better prognosis early, when the evolving patho-anatomic process is less advanced. Thus, the need for early diagnosis of BA cannot be overemphasized amongst health professionals, including midwives, family doctors and health visitors as their exposure to such a rare condition is likely to be limited during their careers.

Abnormality of biochemical markers in BA reflects non-specific cholestasis. Further diagnostic pathways vary depending on the

expertise available locally, but the majority of the centres combine ultrasound, liver biopsy and direct cholangiography for confirmation of BA (4). Percutaneous liver biopsy, performed under local anaesthetic, is diagnostic in around 80% of patients, providing sufficient information to proceed to laparotomy, intraoperative cholangiography and corrective surgery, if required (5). Typical histological features include oedematous portal tracts, with reduplication of the smaller bile ducts and panlobular and intra-portal cholestasis with variable degrees of giant cell transformation and early fibrosis (Figure 1). Neonatal sclerosing cholangitis (NSC) could present with the identical histological features, but these children have pigmented stools.

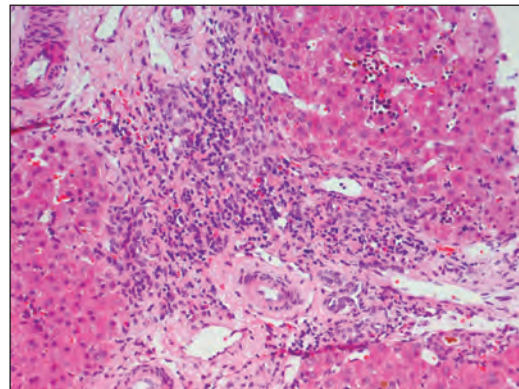


Figure 1 Histopathological findings in the liver biopsy of a seven week old child suggestive of biliary atresia: expanded portal tracts with loose connective tissue and intraportal bile plugs indicative of cholestasis with some portal and interface inflammation (haematoxylin & eosin, x 250)

Some studies have suggested that expert ultrasound scanning could provide important diagnostic indicators either by demonstrating the abnormal outline or absence of the gallbladder (6), or a “triangular” sign, suggestive of portal fibrosis (7). In ambiguous cases, direct radiological methods such as endoscopic retrograde cholangio-pancreatography (ERCP), percutaneous transhepatic cholangiography or cholecystogra-

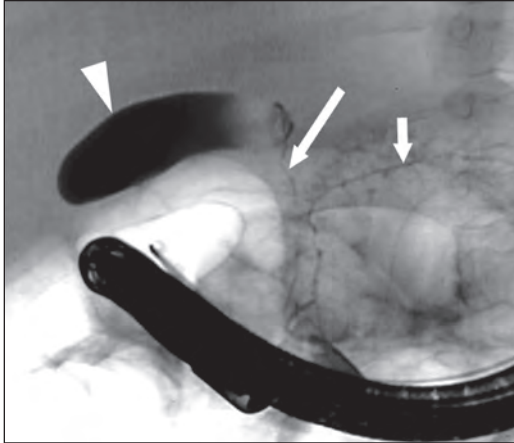


Figure 2 Endoscopic retrograde cholangiopancreatography demonstrating opacification of the pancreatic and common bile duct and the gallbladder, but no visible common hepatic duct and its proximal branches. Biliary atresia type III was confirmed on laparotomy

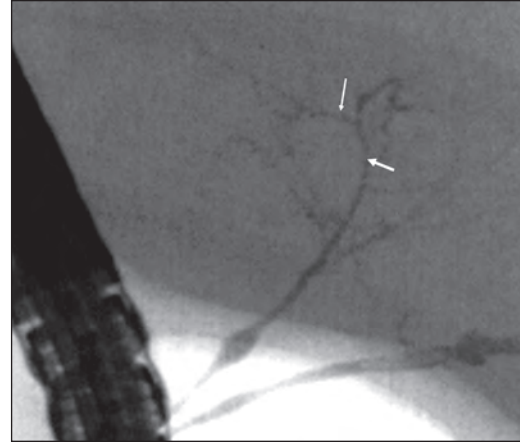


Figure 3 Endoscopic retrograde cholangio-pancreatography in a ten week old infant demonstrating the abnormal appearances of the extrahepatic duct, common hepatic duct and intrahepatic branches of the bile ducts, suggestive of chronic cholangiopathy

phy (PTC) could be considered as they offer the possibility of direct visualisation of the biliary system. Furthermore, during ERCP presence of bile in the duodenum can be documented, excluding BA. Although requiring certain technical skills for this age group, this technique is also the best method to diagnose NSC (8) (Figure 2 and 3).

Clinical variants

The predominant type of BA, seen in 85-90% infants, is a non-syndromic one, with presumed perinatal or early postnatal onset. The remaining 10-15% children have the syndromic (embryonal) variant, associated with splenic malformations (asplenia, polysplenia), midline defects (situs inversus, intestinal malrotation, cardiac isomerism), absence of the inferior vena cava, pre-duodenal portal vein, pancreatic abnormalities, bronchial ciliary dyskinesia and cardiac malformations, such as atrial or ventricular septal defects (9). It is usually referred to as BA-splenic malformation (BASM) syndrome (9, 10). There are also some sporadic

associations with BA, such as with intestinal atresia, Cat eye syndrome, renal abnormalities, but different from the laterality anomalies spectrum described for the BASM syndrome (10). A higher incidence of maternal gestational diabetes and female gender has been observed in the BASM syndrome (9). Post-LT prognosis of children with BASM syndrome has often been described as inferior (11, 12, 13), with anatomical variability, vascular inconsistencies and possibly inferior immune responses due to the splenic involvement as a possible partial explanation (14). The BASM subgroup appears to benefit more from surgery at an earlier age than the non-syndromic one (13).

The Japanese Society of Paediatric Surgeons has suggested macroscopical classification of BA: type I - atresia of the common bile duct with patent proximal ducts, type II - atresia of the hepatic duct with patent proximal ducts, and type III - atresia involving the left and right hepatic ducts at porta. The first two types, much rarer and which affect distal parts of the biliary tree, have been referred to as "correctable", while type III

BA, seen in around 88% of the infants (15) is termed “non-correctable”, as it requires more radical biliary surgery, involving intrahepatic resection deep into the portal plate.

The Japanese surgeon, Morio Kasai, introduced a novel method of corrective biliary surgery, now named after him, in the 1960s (15). His radical operation involves excision of the atretic biliary system and fashioning the Roux-en-Y loop from the patient’s own jejunum (15, 16). Kasai portoenterostomy (KPE) achieves clearance of jaundice in 50-60% of operated children (5, 12) and some 11% have no clinical signs of liver disease after 10-year follow up (17). Nevertheless, one third of all children with BA require LT by 2 years of age, while one more third may need it by adolescence (5, 12). Kasai’s pioneering work was first to recognize the critical role of the patient’s age at surgery, which has been repeatedly observed since worldwide (16, 18). It is conceivable that timely surgery captures BA at earlier stages, when the pathophysiological process has not yet advanced to the proximal intrahepatic biliary radicles, and when re-establishment of the portal flow may still be achievable. Overall, the positive prognostic factors include young age at diagnosis and surgery, experience of the surgical team and specialized long-term medical care (2, 3, 5, 18).

The KPE could also be considered in infants coming to surgery late (i.e. >100 days old), at least as palliation, as long as their chronic liver disease remains clinically compensated, but the outcome success rates decline sharply (19). After the KPE, cirrhotic children often have refractory ascites due to the presence of portal hypertension, peritonitis and ascending cholangitis. In reality, exceptional children presenting with BA at the age of >120 days are usually directly referred for primary LT.

The surgical or short term success of KPE is conventionally defined by normalisation of serum bilirubin by 6 months of age. Re-

cently, one study suggested that good hepatic excretion of isotope on HIDA scanning at that age could predict better outcome at 2 years (20). However, radionuclide studies always need to be clinically interpreted, with preserved hepatic uptake and adequate gut excretion of the isotope not always indicating lack of advanced chronic liver disease and clinical complications.

Pathogenesis

The pathophysiology of BA remains enigmatic, despite its initial description by the Scottish surgeon Thomson more than one hundred years ago (1). Thus far all attempts to explain the aetiology and pathogenesis of BA have remained incomplete (4).

BA is arguably a final clinical phenotype of combined environmental and host pathogenic factors, including defective early morphogenesis or embryonal vascular supply, toxic or infectious triggers, immunogenetic background and/or the aberrant immune reactivity of the young infant (4) (Figure 4).

It is biologically conceivable that a potential cholangiotropic infection could trigger an attack on the bile duct when the adaptive immune responses of the young infant are still defective, and in a susceptible host this could progress to unabated “autoimmune” liver injury. This hypothesis does not account for the occasionally observed twin or even triplet pregnancies with only one baby affected with BA. It was hoped that these rare case reports, antenatally suspected BA (on ultrasound scanning) or the BASM subgroup could shed more light, but unfortunately there is no convincing or definite information yet about the genetic predisposition (4, 9, 21).

Host factors such as HLA phenotype (22, 23, 24) and mutations in *CFC1* or *inv* genes, implicated in determining left-right asymmetry during embryonal development (25, 26) have been suspected to play a role in the

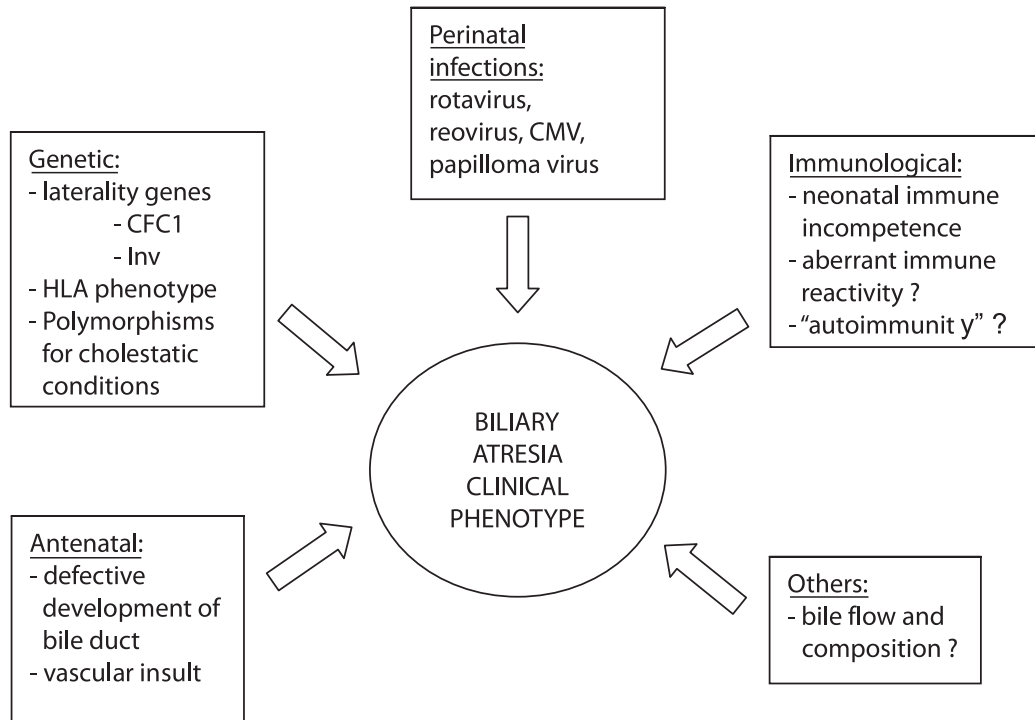


Figure 4 Multifactorial aetiology of biliary atresia

aetiology of BA. Our group, using PCR-based technology, failed to identify any HLA phenotype and cytokine gene polymorphism associations in a multiethnic group of British BA children (22), while two more recent smaller studies, using less sensitive lymphocytotoxicity assays suggested increased prevalence of B8 and DR3 in Egyptian and of HLA-DR2, A24 and B52 in Japanese BA infants (23, 24).

A heterozygous transition c.433G>A in exon 5 of the *CFC1* gene, encoding the CRYPTIC protein, and causing amino acid substitution Ala145Thr has recently been identified in 5 of 10 patients with BASM syndrome, but not all of those 5 had the same clinical phenotype, as illustrated by different types of congenital heart disease (25). As this missense mutation is one of many involved in the laterality defects and was also present in 12.5% of the controls, the authors concluded that it could represent only a co-factor for genetic predisposition to BA

(25). Several infectious pathogens have been proposed to be implicated in animal models and in human BA, including rota virus, reovirus, human papilloma, and herpes group viruses, but their presence was not universally demonstrated (4). Recently, a German group studied the presence of the DNA or RNA of common community viruses in the stored biliary remnants of operated BA children, using a range of PCR-based assays, and found that 21/64 samples were positive for reovirus and 8/74 for cytomegalovirus (27). The study had no control group and the viral prevalence increased with the age of the children, suggesting increased environmental exposure, preventing the authors from interpreting their findings as significant (27).

Inflammation in biliary atresia

BA is a chronic inflammatory process and up-regulation of CD4⁺ and CD8⁺ lympho-

cytes (28, 29), and several proinflammatory cytokines including interferon-gamma, tumour necrosis factor-alpha, interleukin-2 and interleukin-18 was demonstrated both in humans and in rodent models (30, 31, 32). Immunohistochemical staining can demonstrate a significant periportal reactive inflammatory component in the excised biliary remnants (33, 34, 35). Davenport et al. have shown that HLA-DR is aberrantly expressed in the biliary epithelium in BA, with predominantly CD4⁺, natural killer (CD56⁺) T cells and macrophages (CD68⁺) in the inflammatory infiltrate (33). Their increased presence was associated with the poorer outcome in this study (33).

One available animal model for BA is infection of newborn Balb/c mice with a Rhesus group A rotavirus (RRV) strain, which leads to jaundice, progressive inflammation, biliary obstruction and end-stage liver failure within the first month of life (33). The inflammatory cytokines display a Th1 profile, with elevated levels of interferon-gamma and tumour necrosis factor alpha (36). Shivakumar et al. reported the absence of progressive biliary injury in an interferon-gamma knockout Balb/c mouse model following neonatal RRV infection, which would have led to BA in wild type mice. Similarly, CD8⁺ T cell depletion in the same experimental model ameliorates the severity of bile duct obstruction and liver injury (37). Taken together, these observations suggest that targeting interferon-gamma mediated differentiation of CD8⁺ T cells could reduce

biliary obstruction in experimental BA, and by analogy could have a similar effect on the evolution of BA in humans (36, 37).

Mack et al. demonstrated oligoclonal expansion of CD8⁺ T cells in the livers and bile duct remnants of children with BA (35). The predominantly Th1 cytokine “signature” of the immune response in the excised BA remnants at KPE was also suggested, using the gene array chip technique (36). Recently, the same group extended their observations in a rhesus rotavirus (RRV) infected neonatal Balb/c murine model of BA, suggesting that IFN-gamma is the key cytokine mediator and CD8⁺ T cells the main effectors of the inflammatory process in experimental BA (37, 38). Finally, Mack et al. have recently demonstrated that the target of autoreactive cells in the experimental model of BA are bile duct epithelial cells, suggesting the concept of “autoimmune” bile duct injury, based on several pathophysiological similarities between BA and autoimmune disorders (39).

The described experimental data support the concept that immune manipulation could play some role in medical management post-KPE. For many years many centres have been using empirical anti-inflammatory treatment with steroids (40). Several small retrospective and non-randomized studies have reported the beneficial effect of adjuvant treatment with high-dose steroids in the early postoperative period after KPE (40, 41). However, when tested in a randomised placebo-controlled trial, low dose steroids (2 mg/kg/d) failed to influence the short-term

Table 1 Published controlled clinical studies on use of steroids after Kasai portoenterostomy

| Design | Dose | Number of patients | Measures of outcome | Result | Author |
|--|---------------------------------|--------------------|---|--------|--------------------------|
| Randomised Placebo-controlled Double-blind Two-centre | 2 mg/kg D7-21 1 mg/kg D22-28 | 38 38 controls | Bilirubin at 6 and 12 m Native liver at 6 and 12 m | NS | Davenport et al. 2007 |
| Open label Single-centre | 10 mg/kg D1-5 1 mg/kg D6-28 | 20 29 controls | Bilirubin at 6 and 12 m Native liver at 6 and 24 m | NS | Petersen et al. 2007 |

outcome in children with BA (42). Their effect on reducing serum bilirubin, however, appeared to be present in younger infants, possibly related to their immature enzymatic pathways in the liver (42). Another prospective, but small and non-randomised open-label study, using an initial dose of 10 mg/kg/d of prednisolone from D1-D5 post KPE, followed by 1 mg/kg/d from D6-D28, has recently also failed to demonstrate the benefits of steroids for the medium-term outcome (43). Both studies reported that the postoperative use of steroids at these doses was not associated with short-term side effects. Undoubtedly, more controlled studies of the use of anti-inflammatory treatment after KPE are still required.

Medical management

Medical management of children with BA is limited by our incomplete knowledge about its pathogenesis. Table 1 provides the basic guidelines about treatment (Table 1).

Aggressive nutritional support is a principal component of medical management (44). Suboptimal bile flow in children with BA, even after "successful" KPE, secondary to the ongoing fibro-obliterative process in the bile ducts, removed gallbladder and development of chronic liver disease, leads to malabsorption of several nutrients. This pathophysiological problem particularly affects metabolism of the long chain triglycerides and fat-soluble vitamins (44). To improve choleresis, many centres routinely supplement their patients with ursodeoxycholic acid. A recent small French study demonstrated the beneficial effect of this medication after KPE (45).

Milk formulas for cholestatic children should be enriched by medium chain triglycerides (MCT), as they do not require micellar formation for fat solubilization and thus are directly absorbed into portal circulation. Breast feeding can be combined with MCT-

formulas, but this will only be exceptionally sufficient to meet the increased energy requirements of an infant with chronic liver disease, which often range between 120-150 calories/kg/day.

In infants with chronic liver disease, if oral feeding fails to achieve the nutritional requirements, further options are nasogastric bolus and/or continuous/overnight feeding. Small calibre soft nasogastric tubes are well tolerated and generally only minimally increase the bleeding risks from oesophageal varices. In portal hypertension gastrostomy feeding is rarely recommended due to the likelihood of developing further complications such as development of peristomal varices, interference with the existing gastric varices and ultimately complicating surgical aspects of eventual LT. Oral feeding of children with chronic liver disease should be actively encouraged even for a small volume throughout infancy, since after protracted periods on exclusive nasogastric feeding children could develop resistant nutritional, psychological and speech complications, commonly manifesting only after successful LT.

Ascending cholangitis is common after KPE due to the abnormal biliary anatomy, including the absence of papilla Vateri, absent peristalsis in the anastomosis and reduced bile flow. This often facilitates proximal translocation of bacteria from the gut with invasion of the biliary system and the liver, where local defence forces, such as Kupffer cells, may be impaired. The biliary infection could generalize to septicaemia, but could also aggravate the existing liver injury. The initial clinical signs of ascending cholangitis can be very subtle and jaundice may appear late. Therefore, the prompt use of intravenous antibiotics is recommended in children with a history of BA who develop fever in the absence of localising features, lasting for more than 24 hours. Blood and liver biopsy cultures rarely provide positive

identification. One retrospective study suggested the increased prevalence of gram-negative enteric bacteria including *E.coli*, *Pseudomonas aeruginosa*, *Klebsiella pneumoniae*, *Enterobacter cloacae*, *Bacteroides* and *Acinetobacter Baumannii* (46). For repeated or resistant infections extended courses of rotating antibiotics (third generation cephalosporins, co-trimoxazole, ciprofloxacin) could be given.

Children with any chronic liver disease, including BA, are at risk of developing neoplastic changes within the liver. Their follow up must include monitoring of serum alpha-fetoprotein and ultrasound surveillance for focal lesions on a six-monthly basis. Double-phase computerised tomography is often required to assess the vascularity of the suspected lesions, distinguishing malignant changes from more commonly observed regenerative nodules or focal nodular hyperplasia (FNH). Microbubble contrast-assisted ultrasonography is an important new technique for their differentiation, with potential application in the paediatric age group.

Generally, medical management of BA is relatively limited and includes short postoperative oral antibiotic prophylaxis, prolonged fat-soluble vitamin supplementation, ursodeoxycholic acid and optimal nutritional support. Some centres use phenobarbitone and cholestyramine, hoping that microsomal enzyme induction in the hepatocytes and interruption of enterohepatic circulation, respectively, could ameliorate postoperative cholestasis, although there is no formal proof of their benefits (Table 2).

All children with BA should be considered as potential liver transplant recipients from their initial diagnosis. Therefore, in anticipation of long term post-LT immunosuppression, they should undergo early routine immunisation, supplemented with hepatitis A and B, pneumococcal, varicella and meningococcal vaccines. The regular boosters are also recommended, although some reports have observed inferior immune responses in children with BA, possibly explained by the severity of their liver disease (47).

Table 2 Medical management after Kasai portoenterostomy

| |
|--|
| <i>Prevention of infection</i> |
| <ul style="list-style-type: none"> - Antibiotics (cephalosporins, ciprofloxacin, co-trimoxazole) - Standard and additional immunisations (DTP, polio, BCG, Hib, meningitis C, hepatitis A and B, varicella-zoster, pneumococcus, MMR) |
| <i>Improvement of cholestasis</i> |
| <ul style="list-style-type: none"> - Cholagogues (Ursodeoxycholic acid, 20-30 mg/kg/d) - Enzyme inducers (Phenobarbitone, 5 mg/kg/d) - Interruption of entero-hepatic recirculation (Cholestyramine, 2-4 sachets/d) |
| <i>Control of pruritus</i> |
| <ul style="list-style-type: none"> - Rifampicin (5-10 mg/kg/d) - Naltrexone - Ondansentron |
| <i>Nutritional support</i> |
| <ul style="list-style-type: none"> - MCT-based formula milks - Caloric additives - Fat soluble vitamin supplements <ul style="list-style-type: none"> - Vitamin K (1 mg/d) - Vitamin D preparations (2000 IU/day or 60,000 IU/month) - Vitamin E (100 mg/d) - Vitamin A (2500 IU/d or 20,000 IU/month) |

Biliary atresia and liver transplantation

Overall at least about two thirds of children with BA will eventually require LT (48, 49). Indications for LT in children with BA have evolved over the years and are based not only on the major complications of chronic liver disease, such as gastrointestinal bleeding or severe malnutrition, but also the suboptimal quality of life and unsatisfactory academic progress. (50). The majority of experienced centres report one-year patient and graft survival rates in excess of 90% for elective LT (51, 52). Chances of successful LT appear to be increased in older, better nourished and immunologically more mature transplant recipients (11, 51). Primary LT is thus performed only exceptionally for very late presentations of BA, due to the perceived benefits of postponed transplant surgery.

Palliative options in treating portal hypertension secondary to BA, such as transjugular intrahepatic portosystemic or conventional surgical shunts, carry significant risks for worsening encephalopathy and should be discouraged. Complications of BA, prompting consideration for LT, include persistent jaundice with intractable pruritus, advanced portal hypertension with uncontrolled gastrointestinal bleeding or development of hepatopulmonary syndrome, severe malnutrition with failure to thrive and metabolic complications, recurrent life-threatening ascending cholangitis, delayed neurodevelopment and chronic encephalopathy and development of hepatocellular malignancies (12, 50). In the specialised centres, sequential treatment of children with BA, including combination of KPE and timely LT, provide long-term survival of >95% with a normal quality of life (51).

It still remains unclear what proportion of patients with BA will require LT during their lifetime. The results of the longest European studies show that 23% of patients are alive with their native livers 20 years after

KPE (48), while Japanese data are more encouraging, suggesting a dramatic improvement in survival rates over the last 20 years: 10 year survival with native liver in around 66% (49), with satisfactory quality of life and education patterns (52). Successful pregnancies have been reported in long-term survivors of BA, where the compensated biliary disease, undoubtedly present in all, has not been an early obstetric concern (52). The Sendai group reported that out of 14 pregnancies in their 11 medium-term survivors (>16 years post-KPE) there were 2 last-trimester foetal losses (53). It is of note that in 2 patients the pregnancy triggered decompensation, necessitating liver transplantation (53). Therefore, much closer follow up BA patients is required both during the pregnancy and in the early postpartal period, since the enlarged uterus could complicate pre-existing portal hypertension, while the pregnancy-associated increased hormonal burden could endanger hepatic synthetic function. Therefore, it is prudent to perform an elective upper gastrointestinal endoscopy at around four months' pregnancy to assess the severity of portal hypertension and the risk for bleeding.

Conclusions

More than 100 years after its original description, BA remains a puzzling medical condition. The most important part of its management is early detection. This is based on the premise that the shorter postnatal duration of cholangiopathy reduces histological injury and allows an expert surgeon to identify small intrahepatic biliary radicals, increasing the chances of effective re-establishment of the bile flow (18). The relative rarity of the condition makes screening programmes difficult to implement, but the recent successful campaign of distributing stool colour charts to all families of newborns in Taiwanese hospitals, where 90% of infants

with BA were diagnosed within the desired age of <60 days (54), appears affordable and promising. Another positive prognostic factor for BA is management in a centralised tertiary facility, with well-documented benefits demonstrated by studies from the UK and France, where the low-volume centres, performing less than 5 KPEs per year, were found to have much inferior results (2, 3).

Management of BA with KPE as primary corrective surgery, centralized expert medical care and LT as salvage therapy has been well established and provides a satisfactory clinical algorithm in the countries where LT is feasible (50, 51). However, further improvement in non-LT management options, which appear to have been maximally developed already, will not happen until we better understand the pathogenesis of this intriguing condition.

Future research into the basic and clinical aspects of BA must be multicentre and collaborative due to its sporadic nature and relatively low incidence. There are ongoing international initiatives both in Europe and North America trying to address this. The potential areas of the highest interest are: a) introduction of realistic neonatal screening methods, b) host susceptibility studies, where the BASM forms of the condition offer the obvious target, c) evaluation of minimally invasive corrective options, such as laparoscopic surgery against conventional KPE, and d) further testing of different modes of immune manipulation for control of inflammatory response, including use of different steroid regimens or selective anti-cytokine therapies, preferably in a prospective and randomised manner.

References

1. Thomson J. Congenital obliteration of the bile ducts, Oliver & Boyd, Edinburgh; 1892.
2. McKiernan PJ, Baker AJ, Kelly DA. The frequency and outcome of biliary atresia in the UK and Ireland. *Lancet*. 2000;355:25-9.
3. Chardot C, Carton M, Spire-Bendelac N, Le Pommelet C, Golmard JL, Auvert B. Epidemiology of biliary atresia in France: a national study 1986-1996. *J Hepatol*. 1999;31:1006-13.
4. Sokol RJ, Mack C, Narkewitz MR, Karrer FM. Pathogenesis and outcome of biliary atresia: current concepts. *J Pediatr Gastroenterol Nutr*. 2003;37:4-21.
5. Davenport M, Kerkar N, Mieli-Vergani G, Mowat AP, Howard ER. Biliary atresia: the King's College Hospital experience. *J Pediatr Surg*. 1997;32:479-85.
6. Farrant P, Meire HB, Mieli-Vergani G. Improved diagnosis of extrahepatic biliary atresia by high frequency ultrasound of the gall bladder. *Br J Radiol*. 2001;74:952-4.
7. Park WH, Choi SO, Lee HJ, Kim SP, Zeon SK, Lee SL. A new diagnostic approach to biliary atresia with emphasis on the ultrasonographic triangular cord sign: comparison of ultrasonography, hepatobiliary scintigraphy, and liver needle biopsy in the evaluation of infantile cholestasis. *J Pediatr Surg*. 1997;32:1555-9.
8. Shanmugam NP, Harrison PM, Devlin J, Peddu P, Knisely A, Davenport M, et al. Selective Use of Endoscopic Retrograde Cholangiopancreatography in the Diagnosis of Biliary Atresia in Infants Younger Than 100 Days. *J Pediatr Gastroenterol Nutr*. 2009 Aug 11. [Epub ahead of print] PubMed PMID: 19680152.
9. Davenport M, Tizzard SA, Mieli-Vergani G, Hadzic N. Biliary atresia splenic malformation syndrome: a 28 year single center experience. *J Pediatr*. 2006;149:393-400.
10. Davenport M. A challenge on the use of the words embryonic and perinatal in the context of biliary atresia. *Hepatology*. 2005;41:403-4.
11. Diem HV, Evrard V, Vinh HT, Sokal EM, Janssen M, Otte JB, et al. Pediatric liver transplantation for biliary atresia: results of primary grafts in 328 recipients. *Transplantation*. 2003;75:1692-7.
12. Shneider BL, Brown MB, Haber B, Whittington PF, Schwarz K, Squires R, et al. Biliary Atresia Research Consortium. A multicenter study of the outcome of biliary atresia in the United States, 1997 to 2000. *J Pediatr*. 2006;148:467-4.
13. Davenport M, Caponcelli E, Livesey E, Hadzic N, Howard ER. Surgical outcome in biliary atresia: etiology affects the influence of age at surgery. *Ann Surg*. 2008;247:694-8.
14. Taylor RM, Cheeseman P, Davenport M, Tizzard SA, Goldblatt D, Mieli-Vergani G, et al. Humoral immunity in children with biliary atresia splenic malformation syndrome. *Eur J Pediatr*. 2003;162:539-40.

15. Kasai M, Suzuki S. A new operation for "non correctable" biliary atresia portoenterostomy. *Shijitsu*, 1959;13:457-81.
16. Ohi R, Hanamatsu M, Mochizuki I, Chiba T, Kasai M. Progress in the treatment of biliary atresia. *World J Surg*. 1985;9:285-93.
17. Hadzic N, Tizzard S, Davenport M, Singer J, Howard ER, Mieli-Vergani G. Long term outcome of biliary atresia; is chronic liver disease inevitable? *J Pediatr Gastroenterol Nutr*. 2003;37:430-3.
18. Mieli-Vergani G, Howard ER, Portmann B, Mowat AP. Late referral for biliary atresia - missed opportunities for effective surgery. *Lancet*. 1989;1:421-3.
19. Davenport M, Puricelli V, Farrant P, Hadzic N, Mieli-Vergani G, Portmann B, et al. The outcome of the older (>=100 days) infant with biliary atresia. *J Pediatr Surg*. 2004;39:575-81.
20. Castagnetti M, Davenport M, Tizzard SA, Hadzic N, Mieli-Vergani G, Buxton-Thomas M. Hepatobiliary scintigraphy after Kasai procedure for biliary atresia: clinical correlation and prognostic value. *J Pediatr Surg*. 2007;42:1107-13.
21. Hinds R, Davenport M, Mieli-Vergani G, Hadzic N. Antenatal diagnosis of biliary atresia. *J Pediatr*. 2004;144:43-6.
22. Donaldson PT, Clare M, Constantini PK, Hadzic N, Mieli-Vergani G, Howard ER, et al. HLA and cytokine gene polymorphisms in biliary atresia. *Liver* 2002;3:213-9.
23. A-Kader HH, El-Ayyouti M, Hawas S, Abdalla A, Al-Tonbary Y, Bassiouny M, et al. HLA in Egyptian children with biliary atresia. *J Pediatr*. 2002;141:432-4.
24. Yasa T, Tsuji H, Kimura S, Niwa N, Yurugi K, Egawa H, et al. Human leukocyte antigens in Japanese patients with biliary atresia: retrospective analysis of patients who underwent living donor liver transplantation. *Hum Immunol*. 2005;66:295-300.
25. Davit-Spraul A, Baussan C, Hermeziu B, Bernard O, Jacquemin E. CFC1 gene involvement in biliary atresia with polysplenia syndrome. *J Pediatr Gastroenterol Nutr*. 2008;46:11-2.
26. Mazziotti MV, Willis LK, Heuckeroth RO, LaRegina MC, Swanson PE, Overbeek PA, et al. Anomalous development of the hepatobiliary system in the *Inv* mouse. *Hepatology*. 1999;30:372-8.
27. Rauschenfels S, Krassmann M, Al-Masri AN, Verhagen W, Leonhardt J, Kuebler JF, et al. Incidence of hepatotropic viruses in biliary atresia. *Eur J Pediatr*. 2009;168(4):469-76.
28. Rosensweig JN, Omori M, Page K, Potter CJ, Perlman EJ, Thorgeirsson SS, et al. Transforming growth factor beta-1 in plasma and liver of children with liver disease. *Pediatr Res*. 1998;44:402-9.
29. Urushihara N, Iwagaki H, Yagi T, Kohka H, Kobashi K, Morimoto Y, et al. Elevation of serum interleukin-18 levels and activation of Kupffer cells in biliary atresia. *J Pediatr Surg*. 2000;35:446-9.
30. Narayanaswami B, Gonde C, Tredger JM, Hussain M, Vergani D, Davenport M. Serial circulating markers of inflammation in biliary atresia - evolution of the post-operative inflammatory process. *Hepatology*. 2007;46:180-7.
31. Petersen C, Bruns E, Kuske M, von Wussow P. Treatment of extrahepatic biliary atresia with interferon-alpha in a murine infections model. *Pediatr Res*. 1997;42:623-8.
32. Davenport M, Gonde C, Redkar R, Koukoulis G, Tredger M, Mieli-Vergani G, et al. Immunohistochemistry of the liver and biliary tree in extrahepatic biliary atresia. *J Pediatr Surg*. 2001;36:1017-25.
33. Mack CL, Tucker RM, Sokol RJ, Kotzin BL. Armed CD4+ Th1 effector cells and activated macrophages participate in bile duct injury in murine biliary atresia. *Clin Immunol*. 2005;115:200-9.
34. Mack CL, Tucker RM, Sokol RJ, Karrer FM, Kotzin BL, Whittington PF, et al. Biliary atresia is associated with CD4+ Th1 cell mediated portal tract inflammation. *Pediatr Res*. 2004;56:79-87.
35. Mack C, Falta MT, Sullivan AK, Karrer F, Sokol RJ, Freed BM, et al. Oligoclonal expansions of CD4+ and CD8+ T-cells in the target organ of patients with biliary atresia. *Gastroenterology* 2007;133:278-87.
36. Shivakumar P, Campbell KM, Sabla GE, Miethke A, Tiao G, McNeal MM, et al. Obstruction of extrahepatic bile ducts by lymphocytes is regulated by IFN-gamma in experimental biliary atresia. *J Clin Invest*. 2004;114:322-9.
37. Shivakumar P, Sabla G, Mohanty S, McNeal M, Ward R, Stringer K, et al. Effector role of neonatal hepatic CD8+ lymphocytes in epithelial injury and autoimmunity in experimental biliary atresia. *Gastroenterology*. 2007;133:268-77.
38. Bezerra JA, Tiao G, Ryckman FC, Alonso M, Sabla GE, Shneider B, et al. Genetic induction of pro-inflammatory immunity in children with biliary atresia. *Lancet*. 2002;360:1653-9.
39. Mack CL, Tucker RM, Lu BR, Sokol RJ, Fontenot AP, Ueno Y, et al. Cellular and humoral autoimmunity directed at bile duct epithelia in murine biliary atresia. *Hepatology*. 2006;44:1231-9.
40. Dillon PW, Owings E, Cilley R, Field D, Curnow A, Georgeson K. Immunosuppression as adjuvant therapy for biliary atresia. *J Pediatr Surg*. 2001;36:80-5.
41. Meyers RL, Book LS, O'Gorman MA, Jackson WD, Black RE, Johnson DG, et al. High-dose

- steroids, ursodeoxycholic acid, and chronic intravenous antibiotics improve bile flow after Kasai procedure in infants with biliary atresia. *J Pediatr Surg.* 2003;38:406-11.
42. Davenport M, Stringer MD, Tizzard SA, McClean P, Mieli-Vergani G, Hadzic N. Randomized double-blind placebo-controlled trial of corticosteroids following Kasai portoenterostomy for biliary atresia. *Hepatology.* 2007;46:1821-7.
43. Petersen C, Harder D, Melter M, Becker T, Wasielewski RV, Leonhardt J et al. Postoperative high-dose steroids do not improve mid-term survival with native liver in biliary atresia. *Am J Gastroenterol.* 2008;103:712-9.
44. Kaufman SS, Murray ND, Wood RP, Shaw BW Jr, Vanderhoof JA. Nutritional support for the infant with extrahepatic biliary atresia. *J Pediatr.* 1987;110:679-86.
45. Willot S, Uhlen S, Michaud L, Briand G, Bonnevalle M, Sfeir R, Gottrand F. Effect of ursodeoxycholic acid on liver function in children after successful surgery for biliary atresia. *Pediatrics* 2008;122:e1236-41.
46. Wu ET, Chen HL, Ni YH, Lee PI, Hsu HY, Lai HS, et al. Bacterial cholangitis in patients with biliary atresia: impact on short-term outcome. *Pediatr Surg Int.* 2001;17:390-5.
47. Wu JF, Ni YH, Chen HL, Hsu HY, Lai HS, Chang MH. Inadequate humoral immunogenicity to recombinant hepatitis B virus vaccine in biliary atresia children. *Pediatr Res.* 2008;64:100-4.
48. Lykavieris P, Chardot C, Sokhn M, Gauthier F, Valayer F, Bernard O. Outcome in adulthood of biliary atresia: a study of 63 patients who survived for over 20 years with their native liver. *Hepatology.* 2005;41:366-71.
49. Nio M, Ohi R, Miyano T, Saeki M, Shiraki K, Tanaka K. Japanese Biliary Atresia Registry. Five- and 10-year survival rates after surgery for biliary atresia: a report from the Japanese Biliary Atresia Registry. *J Pediatr Surg.* 2003;38:997-1000.
50. Shneider BL, Mazariegos GV. Biliary atresia: a transplant perspective. *Liver Transplant.* 2007;13:1482-95.
51. Davenport M, De Ville de Goyet J, Stringer MD, Mieli-Vergani G, Kelly DA, McClean P, Spitz L. Seamless management of biliary atresia in England and Wales (1999-2002). *Lancet.* 2004;363:1354-7.
52. Howard ER, MacLean G, Nio M, Donaldson N, Singer J, Ohi R. Survival patterns in biliary atresia and comparison of quality of life of long-term survivors in Japan and England. *J Pediatr Surg.* 2001;36:892-7.
53. Sasaki H, Nio M, Hayashi Y, Ishii T, Sano N, Ohi R. Problems during and after pregnancy in female patients with biliary atresia. *J Pediatr Surg.* 2007; 42:1329-32.
54. Hsiao CH, Chang MH, Chen HL, Hsiao CH, Chang MH, Chen HL, et al. Taiwan Infant Stool Color Card Study Group. Universal screening for biliary atresia using an infant stool color card in Taiwan. *Hepatology.* 2008;47:1233-40.